Foot and Ankle Injuries
in the Pediatric Athlete

John R. Faust, M.D.

42nd Annual Symposium on Sports Medicine (Jan. 23rd, 2015)

kids

Disclosures

John Faust, M.D., has no financial relationships to disclose

Overview

- Sever's disease
- Ankle sprains and instability
- Peroneal tendon instability
- Osteochondral lesions of the talus (OLT)
- Ankle impingement
- Ossicles

Sever's disease

Calcaneal apophysitis

- 8% of all overuse injuries in children and adolescents

  Gillespie H. *Curr Sports Med Rep.* 2010;9(5):265-268.
- Typically 8-12 yo
  - Open apophysis required

  Stricker PR. Apophysitis. In: Puffer JC, *ed. 20 Common Problems in Sports Medicine*.New York: McGraw-Hill; 2002:353-366.
- Males 2-3x more than girls

  Frush TJ. *Sports Health*.2009;1(3):201-211.
- 60% bilateral

  Canale ST. Osteochondroses and related problems of the foot and ankle. In: DeLee JC, Drez D Jr, Miller MD, *eds. DeLee and Drez's Orthopaedic Sports Medicine. Principles and Practice*.3rd ed. Philadelphia, PA: Saunders Elsevier; 2010:2142-2170.

Sever's disease

Typical history

- Pain brought on by activity
- Improves with rest, ice, NSAIDs
- Returns with activity
- No pain at rest
- When pain resolves has no pain with weight bearing

Sever's disease

Differential diagnosis of heel pain:

- Calcaneal tumor
  - Benign and malignant
- Calcaneal stress fracture

Radiographs

- Pain with weight bearing
- Parent's request
- Findings: nothing
  - Sclerosis and fragmentation vs. normal development of the apophysis

Sever's disease

Treatment
- Rest, ice, NSAIDs
- Activity modification
- Achilles tendon stretching
- Pad the shoe cleat
- Temporary use of heel cups if desperate
  - Tuli's heel cups
  - Tuli's cheetahs

Have to get serious to improve the pain
- Many wait to finish the season

Recurrence possible/common until skeletally mature

Ankle sprains

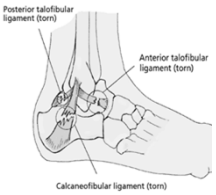

Incidence and frequency:
- Most common sports injury
  - 27,000/day in the US
  - Extreme need for ROM and loading in maximal plantar-flexion
- Peak incidence 15-19 yo
- 70% of basketball players
  - 1/3rd of all high school basketball players over 4 years will have a severe sprain
- 80% recurrence

Rehab is key to re-injury prevention

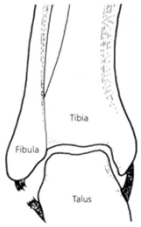

Ankle sprains / instability

Pertinent ligaments

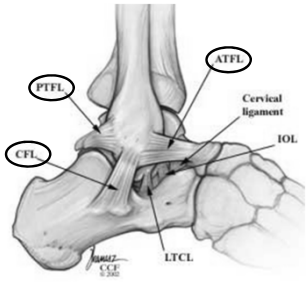

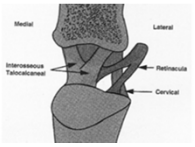

Ankle sprains / instability

History:
- Ankle inversion

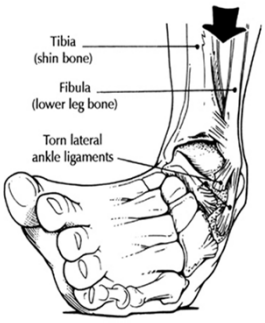

Ankle sprains / instability

Physical exam:
- Anterior and distal to the tip fibula
  - Swelling, bruising
  - Tenderness

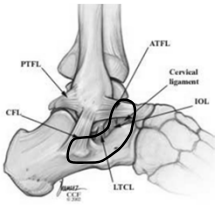

Ankle sprains / instability

Physical exam:
- Anterior drawer test
  - 10° plantarflexion: ATFL
  - Neutral dorsiflexion: CFL

Ankle sprains / instability

Physical exam:
- Anterior drawer test
- Talar tilt test

Ankle sprains / instability

Physical exam:
- Anterior drawer test
- Talar tilt test

Exam under x-ray or fluoro

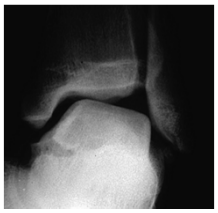

Treatment options

Ankle sprains:
- Non-operative care
- RICE
  - Rest
  - Ice
  - Compression
  - Elevation
- Immobilization
  - Lace-up ankle brace
  - Stirrup brace
  - Fracture-boot
    - Possibly more recurrence than lace-up brace
  - Cast
- Physical therapy – early

Recurrent ankle instability

Treatment options

Ankle sprains:
- Non-operative care
- RICE
  - Rest
  - Ice
  - Compression
  - Elevation
- Immobilization
  - Lace-up ankle brace
  - Stirrup brace
  - Fracture-boot
    - Possibly more recurrence than lace-up brace
  - Cast
- Physical therapy – early

Recurrent ankle instability
- Repeat non-operative care
  - Bracing
  - Physical therapy
- Surgery
  - Repair and plication
  - Reconstruction / augmentation
  - (Shrinkage)

Ankle sprains / instability

Physical therapy
- Pediatric / adolescent programs
- Pain management
- Range of motion
- Strengthening
  - Peroneals – key to rehab
    - Critical for dynamic stabilization
    - Prone to over-use
- Proprioception
- Return to sport

Ankle sprains / instability

Physical therapy – pain management
- RICE
- Modalities
  - Ice
  - Electrical stimulation
  - Taping / bracing



Ankle sprains / instability

Physical therapy – range of motion

- Active – write the alphabet
- Passive
- Active-assisted

Ankle sprains / instability

Physical therapy – strengthening

- Therabands
- Isometric
- Isotonic
  - Concentric
  - Eccentric
- Isokinetic



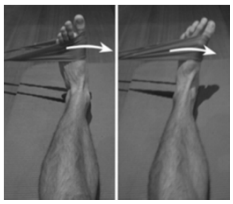

Ankle sprains / instability

Physical therapy – proprioception

- Affected by injury
- Start in early phases
- Advance throughout

Ankle sprains / instability

Physical therapy – return to sports

- More than exercises
- Sport specific skills
- Vary the challenges
- Protect
  - Taping
  - Bracing

Prevent re-injury

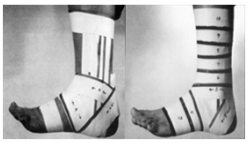

Repair and plication

Broström

Gould modification

Gould N. Foot Ankle 1980

Reconstruction / augmentation

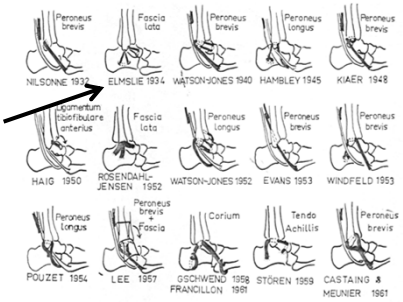

Brostrom L. Acta Chir Scand 1966

Ankle sprains / instability

Summary:
- Very common injury
- Most non-operative
- PT does make a difference
  - More severe
  - More athletic
- Primary repair rarely indicated
- Secondary repair if recurrent instability

Surgery in growing athletes:
- Broström is ideal for most
  - Good tissue
  - Avoids physes
- Augmentation for tissue deficit

Peroneal tendon instability

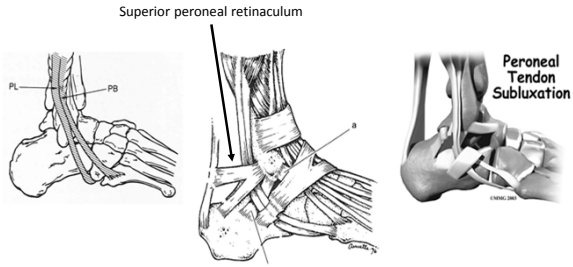

Peroneal tendon instability

Mechanism
- Ankle dorsiflexed
- Hindfoot everted

Acute presentation:
- Very similar to lateral ankle sprain

Chronic presentation
- Visible
- Audible Snap
- Palpable snap

Peroneal tendon instability

Non-operative Care
- Recognize the acute injury
- Immobilize
- Therapy
- 50% successful?

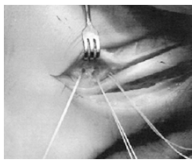

Surgery
- Repair
- Reconstruction

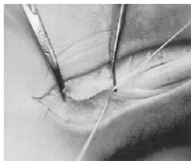

Ferran et al. Sport Med 2006

Peroneal tendon instability

Anatomic repair
- Deepen peroneal groove
  - If growth plate closed

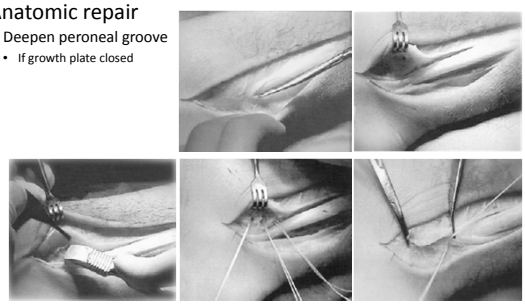

Oliva, F Bull Hosp Joint Dis 2006

Peroneal tendon instability

Pediatric reconstruction:
- Modified Chrisman-Snook
  - Split peroneus brevis
  - Through the epiphysis
  - Into the calcaneus

Forman & Micheli. Foot & Ankle. 2000

Osteochondral Lesion of the Talus (OLT)

Osteochondritis dissecans (OCD) of the talus

- Injury to the surface of the talus
- Cartilage and subchondral bone
- Conservative treatment not very successful
  - Prolonged
  - Risks cartilage

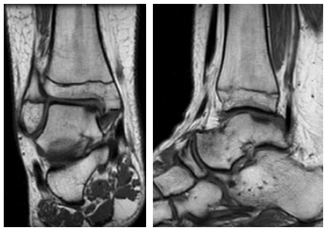

Osteochondral Lesion of the Talus (OLT)

Medial (70%)

- 64% trauma
- Deeper
- Posterior
- Plantarflexion, inversion, ER

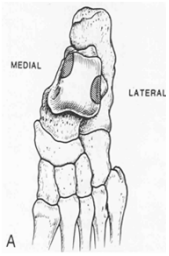

Lateral (20%)

- 100% trauma
- Shallow/wafer
- Anterior
- Dorsiflexion, inversion, IR

Berndt & Hardy. JBJS, 1959
Canale. JBJS, 1980.
Flick & Gould. Foot & Ankle, 1985.

Osteochondral Lesion of the Talus (OLT)

Berndt and Hardy Classification

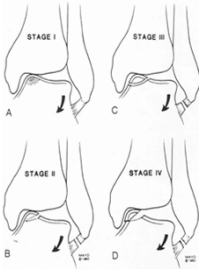

Berndt & Hardy. JBJS. 1959

OCD

Keep it simple

Osteochondral Lesion of the Talus (OLT)

Cartilage surface intact

Cartilage NOT intact

Osteochondral Lesion of the Talus (OLT)

Cartilage surface intact

- Retroarticular drilling

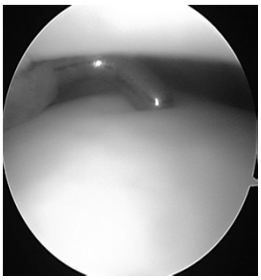

Osteochondral Lesion of the Talus (OLT)

Cartilage surface intact

- Retroarticular drilling

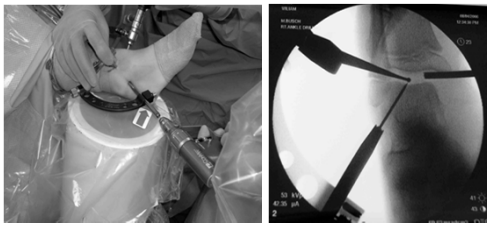

Osteochondral Lesion of the Talus (OLT)

Cartilage surface intact

- Retroarticular drilling

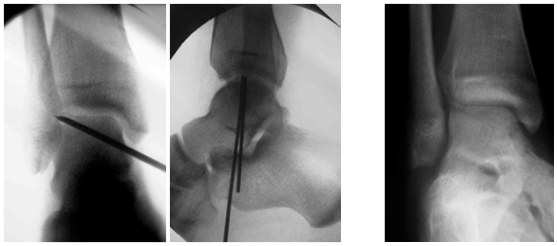

6 weeks post-op

Osteochondral Lesion of the Talus (OLT)

Cartilage surface intact

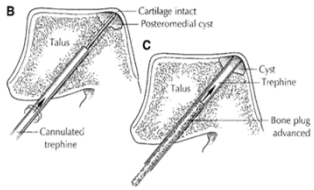

Barnes & Ferkel. Foot Ankle Clin N Am, 2003

Osteochondral Lesion of the Talus (OLT)

Cartilage NOT intact
- Debridement
- Marrow stimulation (microfracture)

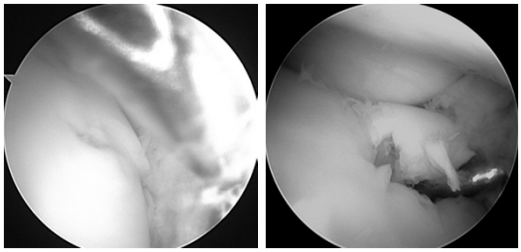

Osteochondral Lesion of the Talus (OLT)

Cartilage NOT intact
- Debridement
- Marrow stimulation (microfracture)

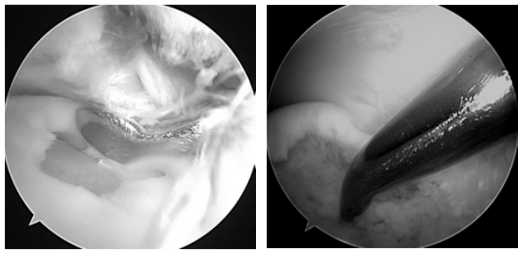

Osteochondral Lesion of the Talus (OLT)

Cartilage NOT intact
- Debridement
- Marrow stimulation (microfracture)

18 months post-op

Ankle impingement

Bone or soft tissue pinched inside the ankle

3 locations
- Anterolateral
- Anterior
- Posterior

Anterolateral ankle impingement

Anterolateral ankle impingement

Etiology:
- Ankle sprains
- Fractures
- Repetitive activities
- Mechanical issues
- Just about anything…

Anterolateral ankle impingement

Treatment:

- PT
- Brace
- Ice
- NSAIDs
- Cast
- Inject
- Arthroscopy
  - Debridement

Anterolateral ankle impingement

Culprits:

- Synovitis
  - Ferkel lesion
  - Meniscoid lesion

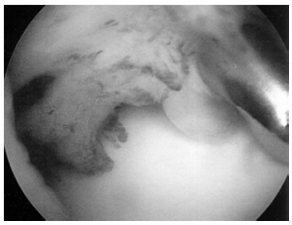

Anterolateral ankle impingement

Culprits:

- Synovitis
  - Ferkel lesion
  - Meniscoid lesion
- Bassett's ligament
  - Accessory fascicle of the anterior inferior tibiofibular ligament (AITFL)

Anterolateral ankle impingement

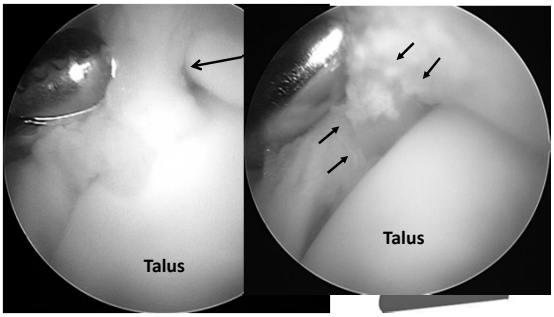

Anterior ankle impingement

Primarily tumblers
- "Landing short" → forced dorsiflexion

Soft tissue impingement initially
- Look for bony lesion like a cam or pincer of the hip
  - Underlying anatomy?
  - Repetitive injury?

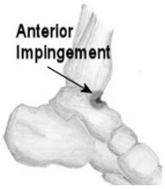

Anterior ankle impingement

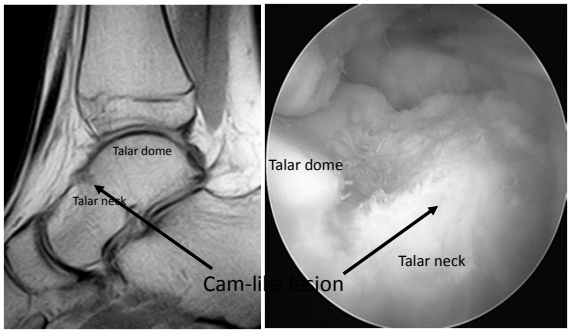

Cam-like lesion

Anterior ankle impingement

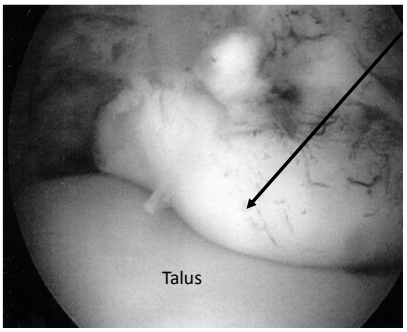

Anterior ankle impingement

Arthroscopic resection

- Before
- After

Anterior ankle impingement

Arthroscopic resection

- Before
- After

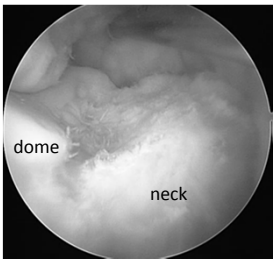

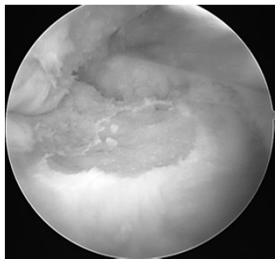

Posterior ankle impingement

Differential diagnosis:

- Chronic synovitis
- Adhesions
- Extension of lateral impingement
- Hypertrophied transverse ligament
- “Meniscus of the ankle”
- “Labrum” of the posterior ankle
- Os trigonum

Gould JF, Ankle Arthroscopy - Pathology and Surgical Techniques

Os trigonum

Separate bony ossicle at the lateral tubercle of the talus
- Present in ~7% of adults
- Ossicle forms between 7-13 years of age
  - Fuses with the talus in most people, otherwise persists as an os trigonum

Different from Steida process
- Enlongated lateral tubercle of the talus

Usually an incidental finding
- Pain
- Snapping/popping

Occasionally symptomatic after trauma or repetitive use

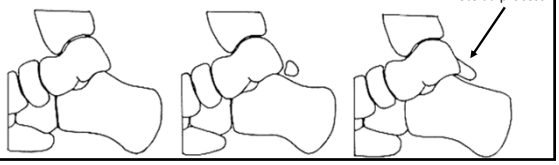

Os trigonum

Sports
- Dance
- Gymnastics
- Competitive cheering
- Marshal arts

Os trigonum

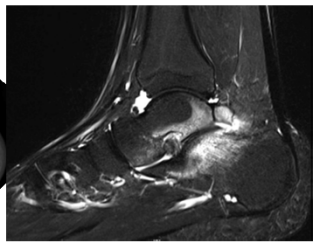

60

Os trigonum

Treatment

- Conservative:
  - Rest and immobilization
    - Activity modification
    - Cast
  - NSAIDs
  - Physical therapy
  - Steroid injection
- Excise for refractory cases
  - open vs. arthroscopic

Micheli. Am J Sports Med. 1992

Os trigonum

Arthroscopic resection

- Set up like a knee
- Exsanguinate before prep
- Foot in lap
- 2.9 mm scope

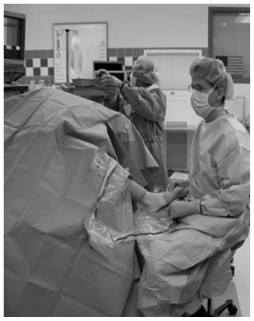

Ankle arthroscopy

"Coaxial" posterior ankle portals

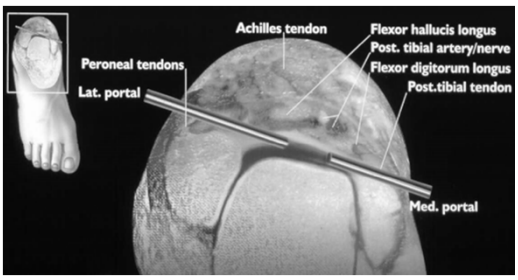

Acevedo & Busch. Coaxial Portals for Posterior Ankle Arthroscopy. Arthroscopy, 2000.

Ankle arthroscopy

Posterior coaxial portals

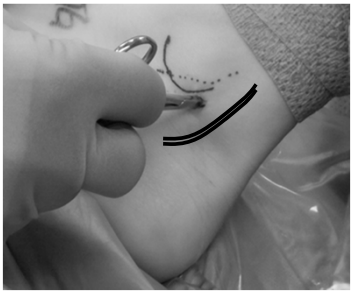

Ankle arthroscopy

Posterior coaxial portals

Os trigonum

Arthroscopic resection

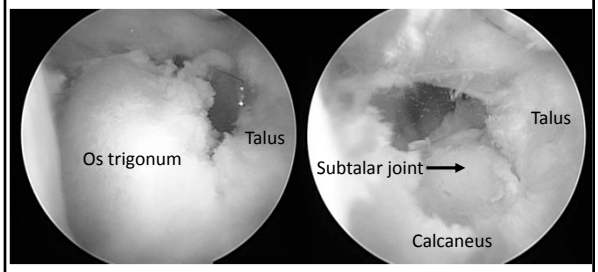

Os trigonum

Arthroscopic resection

- Pre-op
- Post-op

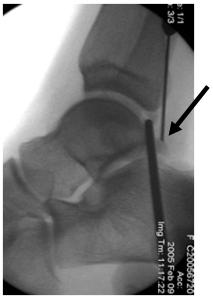

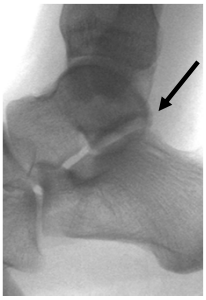

Accessory ossicles

Many ossicles in the foot

- Often incidental
- Correlate with symptoms
- Conservative treatment for most

Os navicular

Os subfibulare

Tip of fibula

Usually an incidental finding

- Ankle sprain
- Snapping/popping

Occasionally becomes symptomatic

Ogden & Lee. JPO. 1990

Os subtibiale

Usually unites

Traumatic vs. developmental

- Can become symptomatic after trauma or repetitive use

Treatment:

- Rest, time
- Rarely more

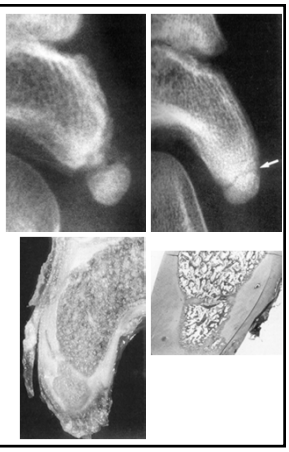

Ogden & Lee. JPO. 1990

Os subtibiale

Arthroscopic resection

- Accessory portal

Os subtibiale

Arthroscopic resection

- Pre-op
- Post-op

Youth sports

Injury prevention

- Parental oversight
- Proper Instruction
- Medical Care and Expertise
- Screening
- Tips

STOP SPORTS INJURIES
Keeping Kids in the Game for Life

www.STOPSportsInjuries.org

faustj@uthscsa.edu

Angie, Sydney (9), Holden (7), Adelaide (4), Everett (2)

Acknowledgments

Mike Busch