

Meniscal Injury

Benjamin G Thomasson, DO
Orthopaedic Sports Medicine Fellow
UTHSCSA
42nd Annual Symposium on Sports Medicine
January 23-24, 2015

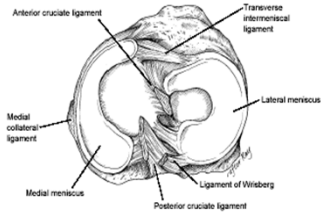
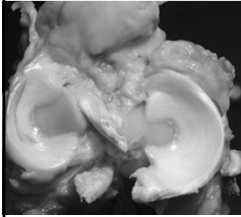
Disclosure

- Benjamin G Thomasson, DO has no financial disclosures
- Special thanks to Dr Matthew Murray for his contribution to these slides.

Epidemiology

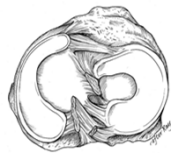- 60-70/100,000 per year
- Arthroscopic Meniscectomy
 - One of the most common orthopaedic procedures
 - 20% of all surgeries at some centers
- Male:Female ratio - 2-4:1
- Younger patients – acute traumatic incident
- Older patients – degenerative tears
- 1/3 of all tears associated with ACL injury
 - ACL Injury – **lateral meniscus** tears more frequent
 - Chronic ACL deficiency – **medial meniscus** injury more prevalent
- Tibial Plateau Fractures
 - Nearly 50% associated meniscal tears

Meniscus Anatomy



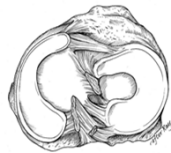Meniscus Anatomy

- Medial Meniscus
 - C-shaped
 - Posterior horn larger than anterior horn
 - Anchored to anterior and posterior bony attachments
- Coronary Ligament
 - Remainder firmly attached to joint capsule
- Deep MCL
 - Thickening of mid-portion of capsular attachment

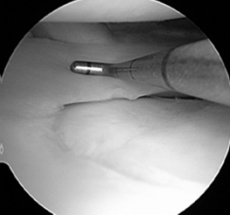


Meniscus Anatomy

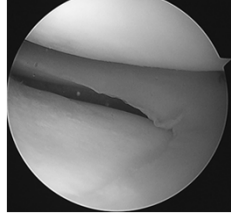
- Lateral Meniscus
 - Semi-Circular configuration
 - Anchored to anterior and posterior bony attachments
 - Much closer than Med Meniscus
 - Anterior horn inserts adjacent to ACL
 - Menisofemoral Ligaments
 - Humphrey – anterior
 - Posterior horn to femur
 - Wrisberg – posterior
 - Can be only posterior attachment in Wrisberg Variant discoid meniscus
- Covers more tibial articular surface
- Capsular attachments much less developed
 - Allows increased translation of lateral meniscus with ROM



Arthroscopic Anatomy



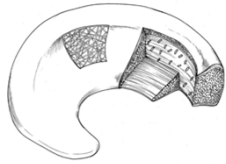
Lateral



Medial

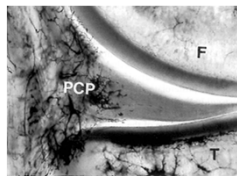
Microstructure

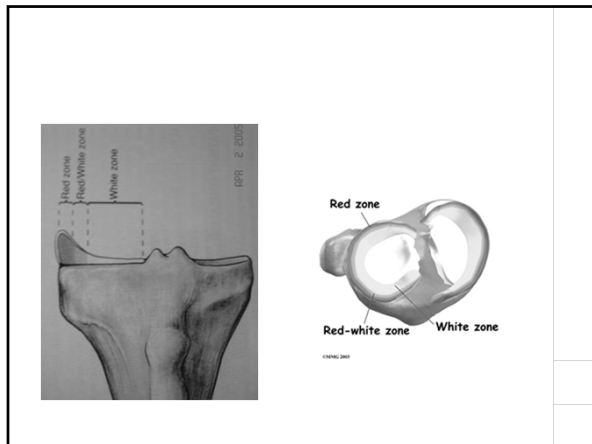
- Type I collagen (90%)
 - Orientation mainly circumferential
 - Allows dispersion of compressive loads
- Some radial fibers at surface and within mid-substance
 - Resist longitudinal tearing
- Mesh orientation at surface
 - Distribution of shear stresses



Blood Supply

- Birth – entire meniscus is vascular
- 9 months – inner 1/3 is avascular
 - Decreased vascularity until 10yo
- Adult Meniscus vascularity
 - Perimeniscal Capillary Plexus
 - Superior and Inferior branches of Medial and Lateral Genicular Arteries
 - Lateral – outer 10-25%
 - Mostly avascular at Popliteal Hiatus
 - Medial – outer 10-30%
- Nerve Fibers
 - Concentrated in outer portion of meniscus
 - Dye et al. – conscious neurosensory mapping
 - Peripheral tissue – mild to moderate discomfort
 - Central tissue – little or no pain awareness
 - Mechanoreceptors in anterior and posterior horns
 - Proprioceptive feedback





Meniscus Function

- 1897 Bland-Sutton
 - "the functionless remnants of the intra-articular leg muscles"

1. Load Sharing
2. Reducing Joint Contract Stresses
3. Passive Stabilization
4. Increasing Congruity/Contact Surface Area
5. Limiting Flexion/Extension Extremes
6. Proprioception

Meniscus Function

- Knee Extension
 - 50-70% of load transmitted through menisci
- Knee Flexion
 - 85% of load transmitted through menisci
- Total Medial Meniscectomy
 - 100% increase in contact stress
 - 50-70% reduction in femoral condyle contact area
- Total Lateral Meniscectomy
 - 200-300% increase in contact stress
 - 40-50% decrease in femoral condyle contact area
- ACL deficient Knee
 - Medial Meniscus is most important resistance to anterior tibial force
 - 50% increased load at full extension
 - 200% increase load at 60deg flexion

History

- Twisting or Hyperflexion Injury
- Pain, swelling
- Locking, catching
- Loss of motion, extension block
- Degenerative Tears
 - Older patients
 - Chronic history of mild swelling and pain
 - Degenerative changes on Xrays



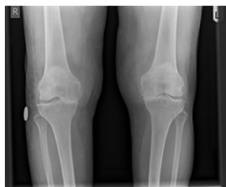
Physical Exam

- Inspection
 - Joint Effusion
 - Quadriceps Atrophy
 - Joint Line Swelling – parameniscal cyst
- Range of Motion
 - Mechanical block in extension
 - Loss of flexion
- Palpation
 - Medial and Lateral joint lines, patellofemoral joint
- Ligament Stability Testing
- Specialized Testing
 - McMurry's Test
 - Apley Grind Test



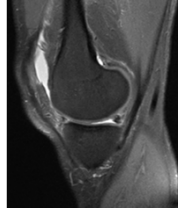Diagnostic Studies

- **Xrays – IMPORTANT!**
 - Helpful for bony pathology and assessing degenerative changes
- Series
 - PA 45deg flexion weight bearing view of both knees
 - Lateral view
 - Merchant view – patellofemoral joint



Diagnostic Studies

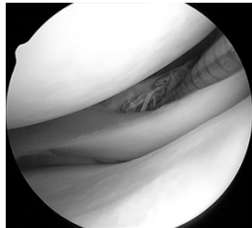
- **MRI**
 - 95% accuracy of detecting meniscal tear
 - **BUT – must correlate clinically**
 - LaPrade – 5.6% tears in asymptomatic 18-39 year olds with normal physical exam
 - Boden – MRI on asymptomatic patients
 - < 45yo – 13% positive for meniscal tear
 - > 45yo – 36% positive for meniscal tear
 - Muellner – equal effectiveness of clinical evaluation compared with MRI



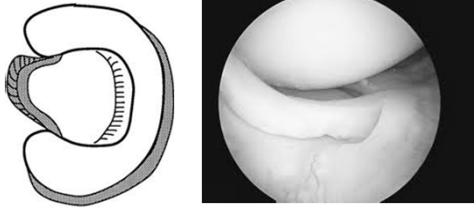
Classification of Meniscal Tears

- **Vertical Longitudinal**
 - Younger patients
 - Often associated with ACL injury
 - Complete – **Bucket Handle**
 - Medial meniscus
 - Mechanical symptoms
 - Incomplete
 - May or may not cause symptoms
- **Oblique – Flap/Parrot Beak**
- **Complex**
 - **Degenerative** – associated with degenerative arthritic changes
- **Radial (transverse)**
 - Isolated or associated with other injuries
 - Complete radial tear disrupts load bearing function of meniscus
- **Horizontal**
 - Often associated with meniscal cysts

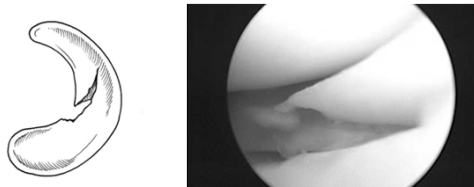
Vertical Longitudinal Tear



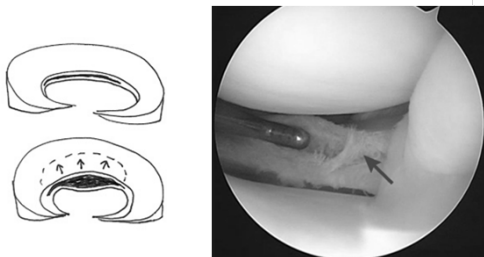
Bucket Handle Tear



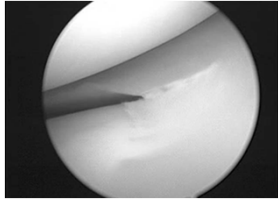
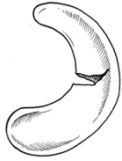
Oblique Parrot Beak Tear



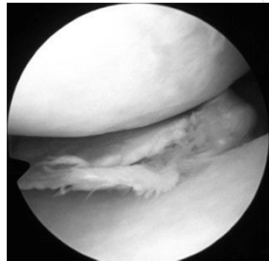
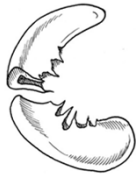Horizontal Cleavage Tear



Radial Tear

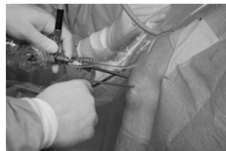

Complex Degenerative Tear



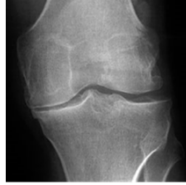
Surgical Indications

1. Symptoms affect
 - Activities of daily living
 - Work
 - Sports
2. Positive physical findings:
 - Joint line tenderness
 - Joint effusion
 - Limited Range of Motion
 - Provocative signs:
 - Pain with Squatting
 - Positive McMurry's or Apley's
3. Failure to respond to non-surgical management
4. Absence of other causes of knee pain identified on Xray or MRI



Total Meniscectomy

- Previously a commonly performed procedure
- Considered benign
- 1948 – Fairbank
 - Joint space narrowing
 - Osteophyte formation
 - Squaring of femoral condyles
- 1987 – Jorgensen
 - 147 athletes, followed at 4.5 and 14.5 years
 - Knee complaints – 53%, 67%
 - Knee Instability – 10%, 36%
 - Radiographic degenerative changes 40%, 89%
 - 46% gave up or reduced sporting activity
- 1992 – Wroble
 - 39 adolescents, 21 year follow up
 - Pain – 71%
 - Stiffness – 68%
 - Swelling – 54%
 - Instability – 41%
 - 90% with abnormal x-rays in affected compartment
 - Overall 63% unsatisfactory results



Arthroscopic Partial Meniscectomy

- 80-90% satisfactory results compared with open total meniscectomy
- Less invasive
- Decreased hospitalization
- Shorter recovery time

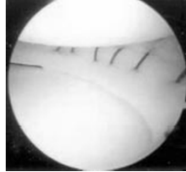


Arthroscopic Partial Meniscectomy

- BUT – not a completely benign procedure
- Still a progression of degenerative changes compared to untreated knees
 - Does not necessarily correlate with subjective clinical results
- Worse results with:
 1. Concomitant Articular Cartilage Damage at time of arthroscopy
 2. Chronic ACL deficiency
 3. Mal-alignment

Meniscal Repair

- 1885: Annandale documented first successful meniscus repair
- Popularized in 1970s by DeHaven and Wirth as alternative to meniscectomy (DeHaven, *Orthop Trans*, 1981; Wirth, *CORR*, 1981)
- Direct open suturing of peripheral tears
- Repair Techniques
 - Open
 - Inside-Out (gold standard)
 - Outside-In
 - All-Inside



Meniscal Repair

- Maintain Meniscal Functions
 - Load bearing
 - Shock absorption
 - Stress distribution
- Prevent degenerative changes
- Beneficial effects of meniscus preservation
 - Partial vs Total Meniscectomy
- So, repair should be even more beneficial.....

Repair vs. Partial Meniscectomy

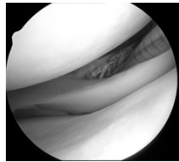
- Difficult to compare
 - Heterogeneity of tears
- Associated injuries
 - ACL
 - Articular Cartilage
- Patient Factors
 - Recreational vs. professional
 - Compliance with rehab

Repair vs Partial Meniscectomy

- Paxton – systematic review 2011
 - Repair has higher re-operation rate (23% vs 4%)
 - Higher in lateral meniscus
 - Lower combined with ACL reconstruction (14%)
 - Meniscal repair has not been definitively shown to reduce osteoarthritic changes when compared with partial meniscectomies
 - BUT – higher re-operation rate may be justified if there is a potential long term benefit of repair
 - There is some evidence that meniscal repair does lead to better radiologic and subjective outcomes over the long-term.

Meniscal Repair

- Indications
 1. Young, active patient
 2. Acute, symptomatic tears
 3. **Complete vertical longitudinal tear**
>10mm
 4. **Peripheral 10 – 30%** or within 3 - 4 mm of meniscocapsular junction (**red-red and red-white zones**)
 5. Unstable tear (> 3 mm displacement with probing)
 6. **Stable knee**
 - 90% success rate with concomitant ACL reconstruction (vs 57% without)
 - 30 – 70% success rate in unstable knees



Meniscal Repair

- Contraindications
 1. Degenerative tear in older patients
 2. White-white avascular tear
 3. Stable, incomplete tears
 4. Infectious, rheumatoid, collagen vascular disease
 5. Non-compliance with rehab

Meniscal Repair

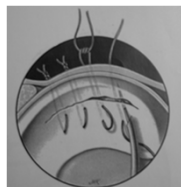
- Improved results combined with ACLR > 90%
 - abundance of blood and growth factors in the joint
 - relatively limited patient activity
 - less aggressive rehabilitation after combined procedures
 - intrinsic condition of the meniscus at the time of repair
- Augmenting isolated meniscal repair?
 - iatrogenic trauma to the surrounding synovium
 - A blood clot
 - microfracture in the notch/notchplasty
 - growing interest in platelet-rich plasma

Repair Techniques

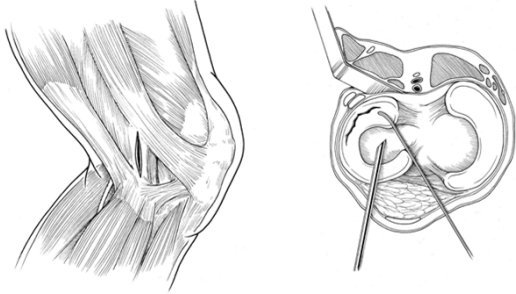
- Inside-Out
- Outside-In
- All-Inside

Inside Out Technique

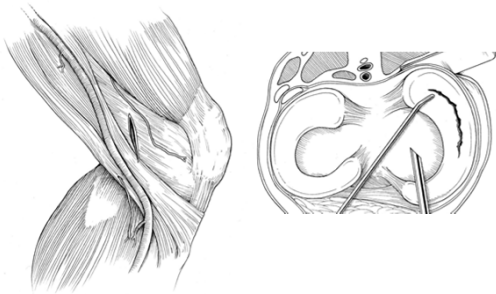
- Gold Standard for Meniscal Repair
 - Open approach to medial or lateral meniscus
 - Double-armed suture with flexible needle threaded through cannula into tear site
 - Sutures retrieved and tied over capsule through open approach



Inside-Out (lateral)

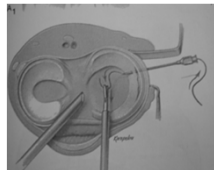
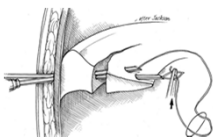


Inside-Out (Medial)



Outside-In Technique

- Useful for anterior horn & middle 1/3 tears
- Must tie Mulberry knot or use wire snare
- Free ends of suture tied over capsule through open incision
- Neurovascular Risk with posterior horn tears



All-Inside

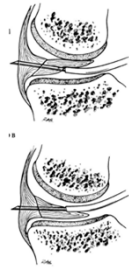- Advantages

- All arthroscopic, no open incisions
- Easy access to posterior meniscus
- Shorter operating time
- Relatively quick, easy insertion
- Implants necessary

- 4 generations:

- 1st – suture hooks
- 2nd – sutures attached to a peripheral bar (T-fix) – required knot tying
- 3rd – rigid bioabsorbable devices (arrows, darts)
- 4th – suture devices, lower profile, allow tensioning (Fas-T-Fix, RapidLoc, Viper)

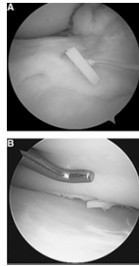
- 4th generation suture devices show comparable biomechanical strength to open and inside-out techniques



All-Inside

- Complications


- Still risk of neurovascular damage
- Implant problems
- Technical problems
- Difficult to access anterior horn

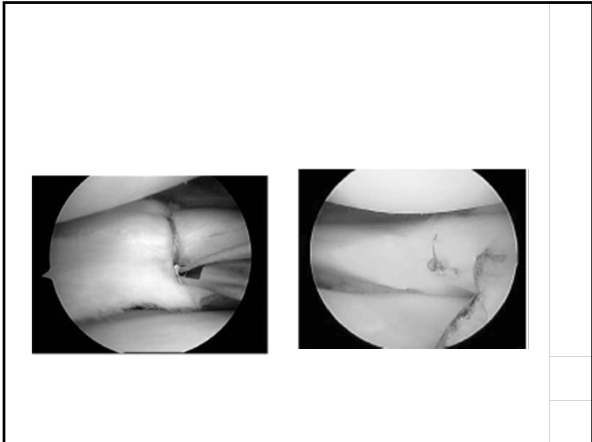


All-Inside Suture devices

- Clinical Results


- Hass 2005
 - 80-90% clinical success at 2 years
 - 91% with ACLR
 - 80% isolated tears
- Barber 2008
 - 83% clinical success at 3 years





Rehabilitation

- **Partial Meniscectomy**
 - Accelerated rehab
 - Immediate WBAT, FROM
 - RTP 3-6 weeks
- **Meniscal repair - controversial**
 - With ACLR
 - No significant alteration in rehab protocol
 - Isolated repair
 - Protected weight bearing
 - 50% PWB for 2 weeks, then advance to WBAT
 - Brace locked in extension for 4 weeks
 - Restricted hyperflexion/squatting for 4 weeks
 - WBAT for Bucket handle and peripheral lesions
 - Weight bearing helps to compress circumferential fibers
 - Reduces meniscus
 - Stabilizes tear
 - NWB for complete radial tears – only exception
 - Circumferential fibers disrupted
 - Weight bearing distracts tear margins
 - RTP 4-6months



© 2014 American Physical Therapy Association

conclusions

1. A good history and physical exam with MRI can accurately diagnose meniscal injury
2. Total meniscectomy compromises meniscus function and accelerates the degenerative process
3. Partial meniscectomy is one of the most commonly performed procedures today, but is not completely benign
4. Meniscal Repair can preserve meniscal tissue and function when performed on the appropriate tear type and patient population
 1. Healing success can be enhanced in combination with ACLR
 2. Early to mid-term data for all-inside repair devices is promising
 3. When performed in isolation, the post-operative rehab course for meniscal repair is prolonged
